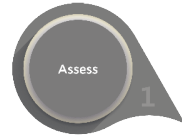

Case Study: Mr H

The Patient



- 90 year old male with no comorbidities.
- Mixed aetiology leg ulcer present for more than 10 years.
- ABPI outside normal parameters - not suitable for compression.
- Patient has not been confident to travel since having the wound.



Assess

Management Goals

Create optimal healing environment by preparing the wound bed, edge and periwound skin:

- Remove non-viable tissue
- Manage exudate
- Manage bacterial burden
- Protect granulation/epithelial tissue
- Rehydrate and protect skin



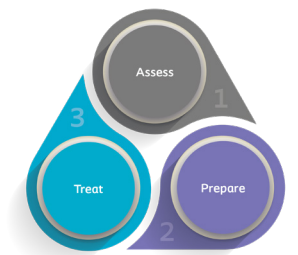Prepare

Alprep® Pad



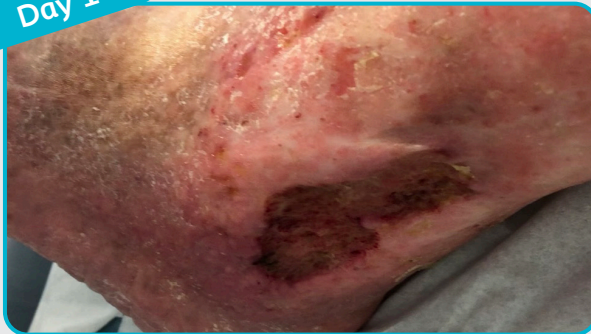Treat

Biatain® Ag Non-Adhesive

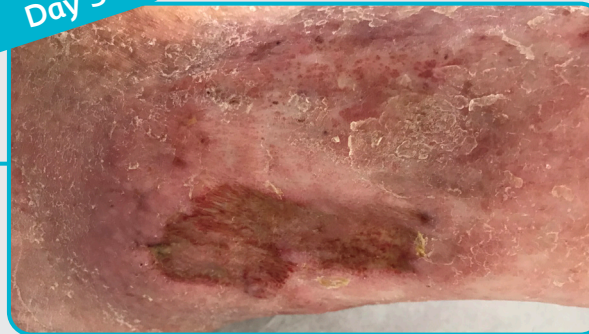


The Coloplast 3 Step Approach

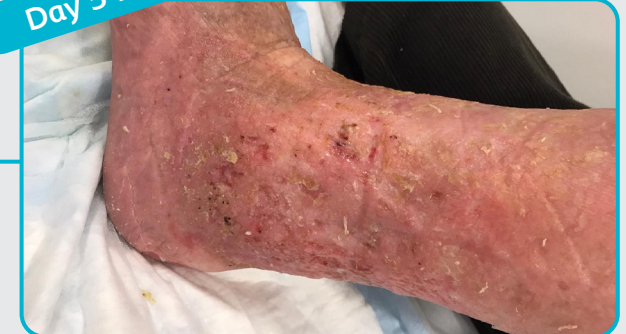Day 1



Day 3



Day 54



Results

- Over more than 10 years of care, Mr H had found wound preparation too painful to tolerate. Since introducing Alprep Pad, which could be tolerated, his wound has made visible and significant process.
- Mr H was able to tolerate 10mmHg compression (liner) after day 3, which he couldn't have done before due to pain and exudate.
- After managing the infection and exudate levels with Biatain Ag Non-Adhesive, Mr H was able to help share his care by using Biatain Silicone and hosiery.
- The wound healed after 54 days of treatment.